BSAVA BRITISH SMALL ANIMAL VETERINARY ASSOCIATION

Check for updates

PAPER

The appearance of canine insulinoma on dual phase computed tomographic angiography

P. Coss[1,*], O. Gilman[†], C. Warren-Smith* and A. C. Major*

*Langford Vets/University of Bristol, Langford Vets, Langford House, Langford, Bristol BS40 5DU, UK
[†]Highcroft Veterinary Referrals, 615 Wells Road, Whitchurch, Bristol BS14 9BE, UK

[1]Corresponding author email: pc17258@bristol.ac.uk

Objectives: To further evaluate the appearance of insulinoma in dogs on dual-phase CT angiography, given the disparity of findings in recent publications. To establish whether CT angiographic localisation of insulinoma correlates with surgical findings.

Materials and Methods: Single centre study of dogs with a final diagnosis of insulinoma which underwent abdominal CT angiography. Scans were retrospectively re-evaluated for specific features by two board-certified veterinary radiologists. These findings were also subsequently compared to surgical and histopathological reports to determine the accuracy of lesion localisation on CT.

Results: Thirty-five cases were included in final analysis, with pancreatic nodules identified in 33. Twenty-one were confirmed as insulinoma with histopathology. Jack Russell Terriers were over-represented. Twenty of 21 cases with confirmed insulinoma and 27 of 33 overall showed hyperattenuation in the arterial phase. The mean size of pancreatic insulinoma on CT was 15.1 mm, and 18.2% were larger than 20 mm. Eighteen of 21 confirmed and eight of 12 suspected insulinomas caused a deformation of the pancreatic shape, with two only identified as a result of this feature as these lesions were isoattenuating throughout the study. Pancreatic insulinoma location at surgery matched that described on the CT images in 17 of 19 cases where location was described in the surgical report.

Clinical Significance: In contrast to recent publications, this study suggests hyperattenuation of insulinomas in the arterial phase is a predominant feature, and that hypoattenuation or isoattenuation are much less common. CT angiography is accurate in prediction of lesion location before surgery in most cases.

Journal of Small Animal Practice (2021) **62**, 540–546
DOI: 10.1111/jsap.13336

Accepted: 05 March 2021; Published online: 26 March 2021

INTRODUCTION

Insulinomas are functional endocrine tumours arising from the β-cells of the pancreas (Cornell & Tobias 2018). These neoplasms primarily secrete insulin but production of other hormones including somatostatin, glucagon, gastrin and pancreatic polypeptide also occurs (O'Brien *et al.* 1987). Largely unregulated secretion of insulin from these tumours persists in the face of low blood glucose levels contrary to normal homeostasis, resulting in episodes of severe hypogylcaemia (Cornell & Tobias 2018). Insulinomas have been reported most commonly in dogs with a mean bodyweight >25kgs, with mean age at diagnosis ranging from 8.5 to 10 years (Leifer *et al.* 1986, Caywood *et al.* 1988, Polton *et al.* 2007). Clinical signs of insulinoma are often intermittent and progressive over several months. Typical signs include weakness, collapse and seizures, which may be precipitated by a period of excitement, fasting or exercise (Kruth *et al.* 1982, Leifer *et al.* 1986, Goutal *et al.* 2012).

Canine insulinomas often demonstrate aggressive biological behaviour, with evidence of metastatic disease found in around

 © 2021 The Authors. Journal of Small Animal Practice published by John Wiley & Sons Ltd on behalf of British Small Animal Veterinary Association
This is an open access article under the terms of the Creative Commons Attribution License, which permits use, distribution and reproduction in any medium, provided the original work is properly cited.

JSAP JOURNAL OF SMALL ANIMAL PRACTICE

45% of cases, most commonly within the abdominal lymph nodes and the liver (Trifonidou *et al.* 1998, Goutal *et al.* 2012). Conversely in humans, insulinomas are generally small, solitary and benign (Klöppel & U Heitz 1988), although their functional nature can result in similar significant and debilitating clinical signs to those recognised in canine patients.

Investigation of suspected insulinoma is challenging as hypoglycaemia may be intermittent during repeated blood tests. Documentation of increased serum insulin levels during a hypoglycaemic episode is considered highly suggestive of insulinoma but histopathology is required for definitive diagnosis (Cornell & Tobias 2018).

In human medicine, a 72-hour fasting test is considered the gold standard non-invasive test for diagnosis of insulinoma (Johansen 1979, Hirshberg *et al.* 2000), with advanced diagnostic imaging studies being performed largely for the purposes of surgical planning. Using fasting tests as gold standard, sensitivity of various imaging techniques has been established (Ahlstrom *et al.* 1990). In humans undergoing dual-phase helical CT angiography (CTA), a sensitivity of up to 94.4% is reported (Gouya *et al.* 2003), although values vary depending on the specific scan protocol used. The appearance of human insulinoma on dual-phase CTA is well described (Balci & Semelka 2001). Similar sensitivity is reported for diffusion-weighted magnetic resonance imaging (MRI) (90.2%), with non-diffusion MRI demonstrated to be marginally inferior (81.4%) (Zhu *et al.* 2017). Reported sensitivity of transabdominal sonography varies widely though is generally significantly lower than CT or MRI (Rayamajhi *et al.* 2017), being commonly stated to be around 60% (Günther *et al.* 1985, Gorman *et al.* 1986).

In canine patients where insulinoma is suspected, extended fasting tests are not routinely performed. As such, diagnostic imaging forms a major part of pre-surgical assessment for both diagnosis and localisation of lesions. CTA represents the most widely used modality for insulinoma diagnosis in referral veterinary medicine, with an assumed sensitivity comparable to that reported in human literature. Extrapolated from the human literature, diagnostic utility of MRI is likely to be similar – however, CT holds a number of practical advantages, including reduced cost, increased availability and lack of an absolute requirement for general anaesthesia. Abdominal ultrasonography, while commonly used as an initial screening test, is limited by user experience and decreased sensitivity, particularly when lesions are small or obscured from view by gastrointestinal content (Robben *et al.* 2005). The use of somatostatin-receptor scintigraphy has been reported in canine patients for diagnostic of insulinoma, but results have been poor (Garden *et al.* 2005) and scintigraphy is not widely available. Despite its common usage and the anecdotal impression that it represents the diagnostic gold standard, there is minimal published data describing the appearance of insulinoma on CTA in dogs; the available literature comprises a small number of case series, most with only small numbers of cases, which have disparate results (Robben *et al.* 2005, Mai & Cáceres 2008, Fukushima *et al.* 2015, Buishand *et al.* 2018). The largest case series of CT findings in canine insulinoma reviewed 27 patients, with dual phase CTA performed in 16 of these (Buishand *et al.* 2018).

The aim of this retrospective, descriptive study is to evaluate the appearance of insulinomas on dual-phase CTA in a larger population of dogs than has previously been documented and to establish whether CTA in canine patients can be used as an accurate guide to the localisation of these lesions for the purposes of surgical planning.

MATERIALS AND METHODS

For this retrospective, cross-sectional study, the electronic medical records database of a large UK small animal referral and teaching hospital was searched between February 2012 and August 2017, for client-owned dogs with a final clinical or histopathological diagnosis of insulinoma. This was accomplished by searching the "history text" of the institution's RxWorks® (Covetrus Technology Solutions) database for the term "insulinoma" within the canine records on the presumption that this would be included in both differential diagnoses of particular cases and also within the original imaging reports. The search was performed by a single operator in August 2017. In the absence of histopathology, clinical diagnosis of insulinoma was based upon documentation of hypoglycaemia alongside blood insulin levels which were concurrently inappropriately high. For inclusion in the study, dogs must also have undergone dual phase CTA of the abdomen during the period of hospitalisation. Sample size was based on the available number of dogs meeting the set inclusion criteria during the study period.

CTA studies were performed under sedation or general anaesthesia according to the preferences of the primary case clinician and attending anaesthetist, with patients positioned in sternal recumbency. Images were acquired using a multidetector 16-slice helical CT scanner [Siemens SOMATOM Emotion 16 (Erlangen, Germany)] with the following helical acquisition parameters: kV 110 to 130, reference mAs 120 (Care Dose4D), slice thickness 1.5 to 3.0 mm, pitch 0.8 and rotation time 0.6 s. Following acquisition of pre-contrast images dogs received a bolus of 600 mg I/kg nonionic iodinated contrast medium (Niopam 300, Bracco UK Ltd; 61.2% w/v Iopamidol equivalent to 300 mg iodine/mL) administered by power injector via an indwelling cephalic or saphenous intravenous cannula at 1-3 mL/second, depending on patient size, before arterial and venous phase post-contrast images were acquired. Timings for contrast medium injection and image acquisition were based on pre-set protocols using a bolus tracking technique but altered as deemed appropriate depending on patient size and sedation protocols, as is standard practice at our institution.

The CTA studies were anonymised and reviewed by two board-certified veterinary radiologists who were blinded to the case details or contents of the original imaging reports but were aware that all cases had a final diagnosis of insulinoma with or without metastatic disease. Images were assessed using a freely available DICOM viewer (Horos™, Horosproject.org). Alterations in windowing and multiplanar reconstructions were employed according to the preferences of the viewers. Any CTA study which included contrast phases deemed to be of poor diag-

17485827, 2021, 7, Downloaded from https://onlinelibrary.wiley.com/doi/10.1111/jsap.13336 by LIN YI CHUN - Readcube-Labtiva , Wiley Online Library on [21/01/2026]. See the Terms and Conditions (https://onlinelibrary.wiley.com/terms-and-conditions) on Wiley Online Library for rules of use; OA articles are governed by the applicable Creative Commons License

nostic quality was excluded. The following data was recorded based on a consensus of both readers: (1) presence or absence of a pancreatic lesion, with assessment of size and distortion of pancreatic shape by the lesion, (2) attenuation of the lesion compared with the surrounding parenchyma pre-contrast and in arterial and venous contrast phases, (3) margination of the lesion (defined as well or poorly marginated), (4) presence of cystic change or mineralisation associated with the lesion, (5) anatomic location of the lesion within the pancreas and (6) evidence of hepatic, lymph node or mesenteric abnormalities suggestive of metastatic disease.

Following image analysis, the clinical history for each patient was reviewed and, where appropriate information was available, lesion location as described by surgical or post mortem reports was recorded and compared with the lesion locations reported in the CTA review. The numerical variables (lesion diameter, patient age and patient weight) were tested for normality using the Shapiro–Wilk test.

Ethical approval for the study was granted by the Animal Welfare and Ethical Review Body of our institution (The University of Bristol)

RESULTS

Eighty-two cases were initially identified from the database search. Of these, 36 cases met the inclusion criteria with 46 cases excluded either due to having an end diagnosis other than insulinoma or due to not having an abdominal CTA study performed at the institution. One further case was excluded at the time of image review as the arterial phase was deemed to be of poor diagnostic quality.

The 35 remaining cases comprised clinical and imaging records from 34 dogs. One dog underwent CTA on two occasions and both studies were included in the final analysis. This patient had surgery following the first study to remove a pancreatic insulinoma. Fourteen months post-surgery, relapse of clinical signs prompted a repeat CTA to assess for evidence of metastasis or local recurrence of the tumour.

The group of included dogs consisted of neutered males (n=11), neutered females (n=19) and entire males (n=4). Patient age and bodyweight were determined by the Shapiro–Wilks test to have a normal distribution. The mean age (±sd) at the time of the CTA study was 8.79 ± 2.71 years (minimum 3 years, maximum 14 years). Mean bodyweight (±sd) was 21.1 ± 11.3 kgs (minimum 3.3 kg, maximum 47.4 kg). Breed distribution of the study population was as follows: Jack Russell Terriers (six), cross breeds (five), Boxers (four), Springer Spaniels (four), Border Collies (two), Labrador Retrievers (two), Pointers (two), Yorkshire Terriers (two) and one each of Airedale Terrier, Cavalier King Charles Spaniel, Chihuahua, Greyhound, Lurcher and West Highland White Terrier.

Twenty-one of 35 cases had insulinoma confirmed histopathologically and 14 of 35 cases were diagnosed clinically but did not have excisional biopsy or post mortem examination performed. In all confirmed cases, tissue samples were obtained from excisional surgical biopsy. Where no histopathology result was available, diagnosis was reached by a combination of suggestive clinical signs with accompanying changes in blood parameters and imaging findings, which were deemed clinically diagnostic by the attending case clinician at the time. In particular, concurrent hypoglycaemia and inappropriately high-blood insulin levels were documented in all cases. This combination of findings alone has been described as sufficient to reach a diagnosis of insulinoma (Nelson 2014).

On image analysis, pancreatic nodules or masses were identified in 33 of 35 cases. One dog had two separate pancreatic lesions present, each with the same appearance on CTA. Lesion size was determined by the Shapiro–Wilk test to have a non-normal distribution, ranging from 3.5 to 44 mm in longest axis with a median of 13 mm (25th percentile of 10 and 75th percentile of 18 mm). A total of 18.2% of pancreatic lesions were larger than 20 mm. Both the smallest and largest lesions were confirmed with histopathology. In 26 of 33 cases, lesions caused notable deformation of pancreatic shape (Fig 1).

In 32 of 33 cases, pancreatic lesions were isoattenuating in the precontrast phase in comparison to the surrounding organ parenchyma. The remaining lesion was hypoattenuating. In 27 of 33 cases, lesions showed hyperattenuation in the arterial phase, with two of 33 remaining isoattenuating and four of 33 being hypoattenuating. In the venous phase, lesions in 15 of 33 cases were hyperattenuating to their surroundings, 17 of 33 were isoattenuating and one of 33 hypoattenuating.

Table 1 shows the frequency of the enhancement profiles observed for the pancreatic lesions. In 42.4% of cases, the observed profile was pre-contrast isoattenuation, progressing to hyperattenuation in both the arterial and venous phases (Fig 2). Pre-contrast isoattenuation, followed by arterial phase

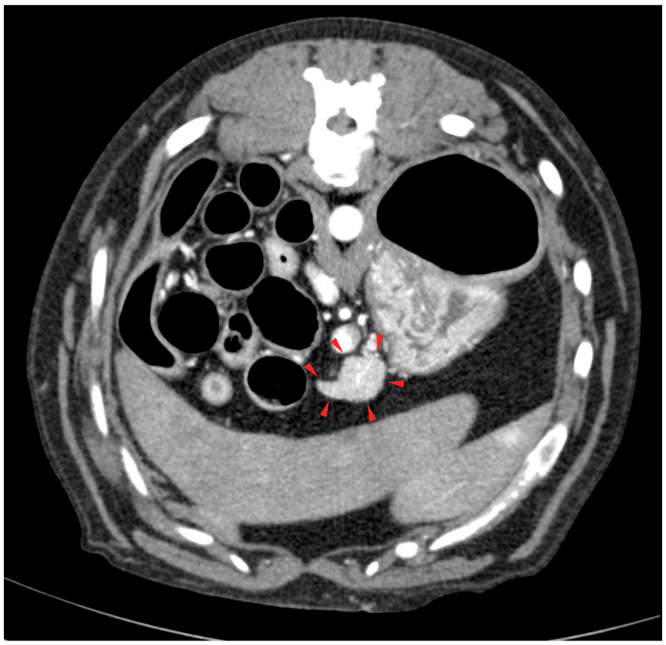

FIG 1. An arterial contrast phase image from an abdominal CT study demonstrating an insulinoma causing deformation of the pancreatic shape (denoted by red arrow heads)

17485827, 2021, 7, Downloaded from https://onlinelibrary.wiley.com/doi/10.1111/jsap.13336 by LIN YI CHUN - Readcube-Labtiva , Wiley Online Library on [21/01/2026]. See the Terms and Conditions (https://onlinelibrary.wiley.com/terms-and-conditions) on Wiley Online Library for rules of use; OA articles are governed by the applicable Creative Commons License

Table 1. Attenuation patterns of pancreatic insulinomas through each contrast phase

Pre-contrast	Arterial phase	Venous phase	Number
Isoattenuation	Hyperattenuation†	Hyperattenuation	14
Isoattenuation	Hyperattenuation	Isoattenuation	12
Isoattenuation	Isoattenuation	Isoattenuation	2
Isoattenuation	Hypoattenuation	Isoattenuation	2
Hypoattenuation	Hyperattenuation	Isoattenuation	1
Isoattenuation	Hypoattenuation	Hypoattenuation	1
Isoattenuation	Hypoattenuation†	Hyperattenuation	1

†One lesion additionally showed rim enhancement in the arterial phase

hyperattenuation, with a return to isoattenuation in the venous phase was observed in 36.4% of cases. Four lesions (12%) were hypoattenuating or predominantly hypoattenuating in the arterial phase, with one demonstrating arterial rim enhancement. Of these four, two became isoattenuating in the venous phase, one became hyperattenuating and the last remained hypoattenuating. The two lesions which were isoattenuating in the arterial phase were also isoattenuating on the pre-contrast and venous phases; these were only detected due to the local deformation of pancreatic shape which they caused.

Lesions were well marginated in 18 of 33 cases and poorly marginated in 15 of 33 cases (Fig 3). Cystic change or mineralisation was not identified in any lesion.

Table 2 shows the anatomic locations of the 34 pancreatic lesions identified in 33 patients by CTA. Anatomic location of lesions identified at surgery was recorded in 19 of 21 cases. Surgical localisation matched imaging localisation in 17 of 19 cases (89%). In one case, the CTA localised the lesion in the body of the pancreas and the surgery report described the lesion as being in the left lobe. In the other case, CTA localised the lesion in the body to proximal left lobe of the pancreas whereas the surgery report placed it in the body to proximal right lobe.

Two of 35 CTA studies had no pancreatic lesion detected. One was the dog in which a pancreatic insulinoma had been previously surgically excised, which in its second study showed evidence of hepatic metastatic disease, although this was not confirmed histologically. In the other a solitary abnormal lymph node adjacent to the pancreas was identified. At surgery, this lymph node was found to be closely adhered to the pancreas and was subsequently confirmed histopathologically to contain insulinoma metastasis. A primary pancreatic insulinoma was not identified at surgery in this case. There were no cases in which a pancreatic lesion was identified at surgery which was not evident on CTA.

On image review, metastases within the liver, abdominal lymph nodes and/or mesentery were suspected in 21 of 35 cases. Hepatic nodules were most common, occurring in 15 cases, 14 of which had concurrent pancreatic lesions. Hepatic nodules showed the same arterial phase enhancement pattern as the identified pancreatic lesions in 10 of 14 cases (71.4%). Of those cases with matching arterial phase enhancement, hepatic biopsies were obtained surgically in four cases, confirming hepatic metastasis in three cases. Of the four cases where hepatic lesions displayed different arterial enhancement to the pancreatic lesions only one was treated surgically, with pancreatic insulinoma confirmed but hepatic biopsy showing no evidence of insulinoma metastasis.

Twenty-one cases involved surgical pancreatic biopsies, all of which confirmed the diagnosis of insulinoma. In 11 of these additional hepatic or lymph node, biopsies were taken, confirming abdominal metastasis in six cases. In two of these cases, lymph nodes metastases were detected which were not apparent from the CT images.

DISCUSSION

This study describes the CTA appearance of pancreatic insulinoma with and without evidence of abdominal metastatic disease in a larger population of canine patients than previously reported.

In a review of previous studies, insulinomas were reported most commonly in medium to large breed dogs with a mean bodyweight >25 kg (Goutal *et al.* 2012). Our study population had a greater prevalence of smaller breed dogs, with a lower mean bodyweight. In particular, Jack Russell Terriers (JRT) appeared overrepresented, comprising six of 34 patients and being the most prevalent breed in the study. During the study period, JRTs comprised 3.92% of canine patients seen by our hospital; however, they represented 16.7% of the population within the study. A breed predisposition for insulinoma has not previously been reported for JRT, however a previous insulinoma study including 27 dogs, also reported this breed to be the most prevalent (Buishand *et al.* 2018). A larger, historical study into 73 dogs with insulinomas reported none within JRTs though details of the number presenting to the hospital during that period were lacking, making it difficult to draw accurate conclusions (Caywood *et al.* 1988). Nonetheless, a previously unrecognised breed predisposition is considered possible.

Pancreatic insulinomas in humans are typically small and are only rarely reported to alter the contour of the pancreas (Ahlstrom *et al.* 1990). In cases of human insulinoma, 10% of pancreatic nodules are reported to be larger than 20 mm (Okabayashi *et al.* 2013), whereas in our study almost twice the proportion of canine insulinomas exceeded this size. As a result of their generally larger dimensions the majority of the lesions we identified caused distortion of the shape of the pancreas. The reason for this species discrepancy is unclear; it may be that clinical signs prompting investigation are noticed earlier in human patients, or that tumour growth rates may be faster in canine insulinomas. The variable prevalence of organ deformation may simply result from the differing species anatomy, where the pancreas in dogs is typically more slender than in humans.

The diagnosis of canine insulinoma through the use CT has long been based on detection of a "classical" enhancement pattern, predominantly the presence of arterial phase hyperattenuation (Mai & Cáceres 2008). Non-contrast CT has not been considered to have high diagnostic utility as in the majority of reported cases these lesions present as isoattenuating to the surrounding pancreatic parenchyma pre-contrast. Our findings were consistent with this. However, the high prevalence of lesions which deformed the shape of the organ, rendering them visible pre-contrast even when isoattenuating, leads us to suggest that there may still be some merit in performing non-contrast CT examination of patients

17485827, 2021, 7, Downloaded from https://onlinelibrary.wiley.com/doi/10.1111/jsap.13336 by LIN YI CHUN - Readcube-Labtiva , Wiley Online Library on [21/01/2026]. See the Terms and Conditions (https://onlinelibrary.wiley.com/terms-and-conditions) on Wiley Online Library for rules of use; OA articles are governed by the applicable Creative Commons License

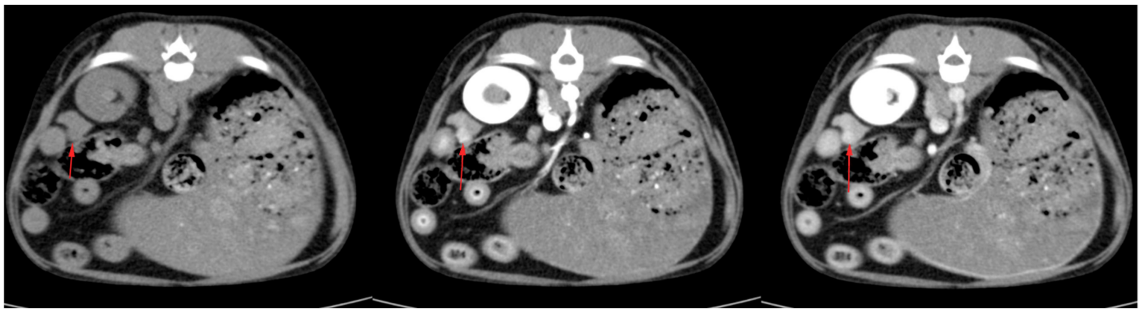

FIG 2. A contrast series through three identical slices of an abdominal CT study, documenting from left to right: (1) precontrast isoattenuation, (2) arterial phase hyperattenuation and (3) venous phase hyperattenuation of an insulinoma, relative to the surrounding pancreatic parenchyma (denoted by red arrows)

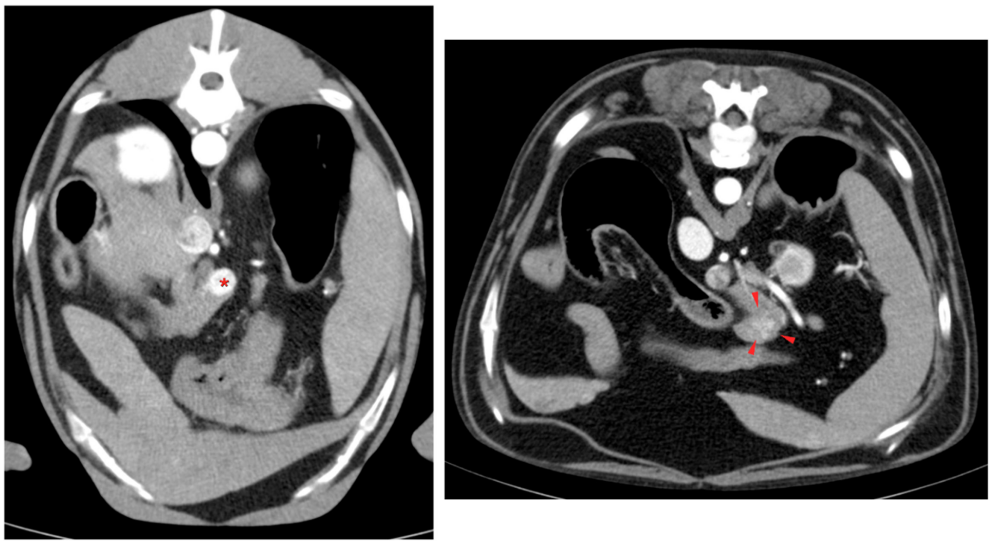

FIG 3. Two separate single arterial contrast phase images from abdominal CT scans of different patients, showing examples of a well marginated insulinoma in the left image (denoted with a red star) and a poorly marginated insulinoma in the right image (denoted by red arrowheads)

Table 2. Locations of insulinomas within the pancreas as visible on CT angiography

Position on CT	Distal right lobe	Proximal right lobe	Body/proximal right lobe	Body	Body/proximal left lobe	Proximal left lobe	Distal left lobe
Number	7	2	1	5	0	2	17

suspected of having insulinoma in cases where administration of contrast may be clinically contraindicated.

Arterial phase hyperattenuation has been an anecdotally well-established feature of canine insulinomas for over a decade, based on early veterinary case reports (Mai & Cáceres 2008) and published data from the human field (Liu *et al.* 2009). Some veterinary literature in the intervening period has questioned the validity of this, with arterial phase hyperattenuation identified in as little as 22.2% of one series (Fukushima *et al.* 2015) and 47.1% of another (Buishand *et al.* 2018). Conversely, the data we present here adds further evidence that arterial phase hyperattenuation is indeed a predominant feature in canine insulinoma.

Arterial phase hypoattenuation was demonstrated by only 12.1% of the pancreatic insulinomas within this study, correlating well with human reports (Ahlstrom *et al.* 1990) but contrasting with a previous veterinary case series where a higher proportion of pancreatic insulinomas appeared hypoattenuating in the arterial phase (Fukushima *et al.* 2015).

The data we present from this study highlight the importance of the arterial phase where insulinoma is suspected. Every pancreatic lesion which demonstrated altered contrast enhancement in comparison with surrounding tissue at any stage post-contrast was clearly detectable during the arterial phase. This has not been a finding of previous studies where timings for contrast phases were pre-set at 15 and 30 seconds after the start of injection – in the current study bolus tracking was used as part of the scan protocol, and this is felt to be a more precise method, potentially increasing sensitivity (as was suggested in the more recent of the previous studies) (Fukushima *et al.* 2015, Buishand *et al.* 2018). The "vascular blush" of insulinomas can be short lived; therefore, it stands to reason that it may be missed with less accurate timing of arterial phase acquisition (Noone

17485827, 2021, 7, Downloaded from https://onlinelibrary.wiley.com/doi/10.1111/jsap.13336 by LIN YI CHUN - Readcube-Labtiva , Wiley Online Library on [21/01/2026]. See the Terms and Conditions (https://onlinelibrary.wiley.com/terms-and-conditions) on Wiley Online Library for rules of use; OA articles are governed by the applicable Creative Commons License

17485827, 2021, 7, Downloaded from https://onlinelibrary.wiley.com/doi/10.1111/jsap.13336 by LIN YI CHUN - Readcube-Labtiva , Wiley Online Library on [21/01/2026]. See the Terms and Conditions (https://onlinelibrary.wiley.com/terms-and-conditions) on Wiley Online Library for rules of use; OA articles are governed by the applicable Creative Commons License

et al. 2005). Overall sensitivity of the arterial phase for detection of pancreatic insulinomas was 94.0% in this study, comparable to the 86.1% sensitivity reported in a previous human study (Liu *et al.* 2009).

Two insulinomas within this study exhibited rim enhancement during the arterial phase. It is possible that this appearance may relate to imprecision of the timing of acquisition of the arterial phase even with the use of bolus tracking. If it is reasonably assumed that enhancement of nodules begins peripherally then extends centrally then an early arterial phase would result in this appearance.

This study did not include assessment of "delayed" phase post-contrast series' (typically acquired around 90 seconds following contrast injection) largely because they are not performed as standard at our institution. In two cases, pancreatic lesions were isoattenuating throughout all acquired contrast phases and were detected only due to the organ deformation they caused. The possibility cannot be excluded that these two lesions may have shown increased contrast uptake during a delayed phase, as this has been reported to occasionally occur, highlighting lesions not evident in earlier phases (Fukushima *et al.* 2015; Buishand *et al.* 2018). However, within the human medical literature, insulinomas which are isoattenuating throughout all phases, including a delayed phase, are well described (Fidler *et al.* 2003).

The margination of pancreatic lesions in our patient population was variable, with only around half being well marginated. Liu *et al.* (2009) demonstrated that most human insulinomas have well-defined edges. This difference suggests differing biological behaviour leading to a greater degree of locally infiltrative growth in canine tumours.

No cystic changes or mineralisation of lesions was evident in this study. In humans, cystic changes are described but only as uncommon occurrences (Sheth *et al.* 2002). It has been theorised that this lack of cystic degeneration, even within large tumours, is due to the rich vascularisation present, which grows as the mass enlarges (Balci & Semelka 2001). The mineralisation on the other hand, is not an uncommon finding in human pancreatic endocrine tumours, being present in up to 20% of cases (Balci & Semelka 2001). Interestingly, in humans mineralisation is most prominent in malignant islet cell tumours (Imhof & Frank 1977) which could be considered to be the equivalent of the generally malignant canine lesions. This contributes further evidence to the notion that human and canine insulinomas have distinctly different biological behaviour.

In the majority of cases (89%), anatomic location of the pancreatic lesion at surgery was consistent with that reported from the CT images. Where disparities existed they are difficult to explain, though it has previously been suggested that variability in duodenal location could lead to a difficulty in prediction of locations within the pancreas (Buishand *et al.* 2018). In terms of surgical planning, the accuracy of CT compares favourably to other modalities, such as somato-statin-scintigraphy, in which accuracy for localisation of detectable insulinomas was shown to be only 20% in a previous canine study (Garden *et al.* 2005).

Suspicion of metastatic disease on the basis of CT findings was common within this study, as in previous reports (Caywood *et al.* 1988, Trifonidou *et al.* 1998, Robben *et al.* 2005). Unfortunately, few of our cases had histopathological confirmation of metastases, mainly due to a lack of submitted tissue biopsies. It has been shown previously that a large number of suspected metastases in insulinoma cases, can in reality reflect other disease processes (Tobin *et al.* 1999) and this may also be the case in our population. Our study population comprised predominantly middle age to older dogs; a group where the presence of benign hepatic nodules, e.g. resulting from benign nodular hyperplasia, is a common finding (Bergman 1985). Our study also demonstrated that metastatic lesions may not be evident on CTA as in two cases lymph node metastases were only identified on histopathology following surgical exploration and excision.

Interestingly, nearly half of the patients who went on to undergo surgical treatment in this study had evidence of metastases identified on CTA, indeed four had multiple hepatic and abdominal lymph node metastases suspected. It has however been previously suggested that surgical management is not inappropriate for these advanced cases and clinical stage was not found to be a significant prognostic factor in one surgical study (Caywood *et al.* 1988).

There are some limitations to this study, with one significant limitation being that not all cases had confirmation of primary pancreatic insulinoma and/or regional metastasis with histopathology. The cases which were not confirmed were diagnosed by supportive blood test results and clinical signs. Due to the fact that imaging results played at least some role in the diagnosis of the majority of these cases, this introduces a bias when analysing the unconfirmed cases. Other insulinoma patients without clear imaging findings may in theory have been excluded if this meant an end diagnosis was not reached. While our study population is larger than any other previously reported it remains a small number, representing a further limitation. Immunohistochemistry was not performed on biopsy samples within this study in order to definitively prove neoplastic insulin production. This may have yielded further information for comparison as pancreatic neoplasms can produce multiple hormonal profiles; however, clinical signs generally relate only to the overproduction of insulin, which was observed in all of the cases reported here (O'Brien *et al.* 1987).

In conclusion, we present an analysis of the largest record of CTA findings for canine patients with insulinoma to date. Within our study population, Jack Russell Terriers and smaller dogs in general were over-represented in comparison to previous reports. We provide further evidence that, in contrast to recent publications, hyperattenuation of insulinomas within the arterial phase is a predominant feature and also that hypoattenuation is a less common alternative arterial phase appearance. A minority of pancreatic lesions demonstrated isoattenuation during all contrast phases; it is assumed that similar, smaller lesions, which do not distort pancreatic shape, would therefore not be detectable using CTA and so would result in false negative diagnosis in circumstances where imaging findings are heavily relied upon. The use of CTA for surgical planning was generally accurate for pancreatic lesions, although some lymph node metastases were detected at surgery but not via CTA.

Further research and larger studies would be valuable as well as research into CT techniques not yet routinely applied to veterinary imaging, *e.g.* volume perfusion CT, which has led to improved detection sensitivity for human insulinomas (Zhu *et al.* 2017).

Conflict of interest

None of the authors of this article has a financial or personal relationship with other people or organisations that could inappropriately influence or bias the content of the paper.

References

Ahlstrom, H., Magnusson, A., Grama, D., *et al*. (1990) Preoperative localization of endocrine pancreatic tumours by intra-arterial dynamic computed tomography. *Acta Radiologica* **31**, 171-175

Balci, N. C. & Semelka, R. C. (2001) Radiologic features of cystic, endocrine and other pancreatic neoplasms. *European Journal of Radiology* **38**, 113-119

Bergman, J. R. (1985) Nodular hyperplasia in the liver of the dog: an association with changes in the Ito cell population. *Veterinary Pathology* **22**, 427-438

Buishand, F. O., Grosso, F. R. V., Kirpensteijn, J., *et al*. (2018) Utility of contrast-enhanced computed tomography in the evaluation of canine insulinoma location. *Veterinary Quarterly* **38**, 53-62

Caywood, D. D., Klausner, J. S., O'L.ary, T. P., *et al*. (1988) Pancreatic insulin-secreting neoplasms: clinical, diagnostic, and prognostic features in 73 dogs. *Journal of the American Animal Hospital Association* **24**, 577-584

Cornell, K. & Tobias, K. (2018) Pancreas. In: Veterinary Surgery: Small Animal. 4th edn. Eds S. Johnston and K. Tobias. Elsevier, St. Louis, MO, USA. pp 1899-1990

Fidler, J. L., Fletcher, J. G., Reading, C. C., *et al*. (2003) Preoperative detection of pancreatic insulinomas on multiphasic helical CT. *AJR. American Journal of Roentgenology* **181**, 775-780

Fukushima, K., Fujiwara, R., Yamamoto, K., *et al*. (2015) Characterization of triple-phase computed tomography in dogs with pancreatic insulinoma. *Journal of Veterinary Medical Science* **77**, 1549-1553

Garden, O. A., Reubi, J. C., Dykes, N. L., *et al*. (2005) Somatostatin receptor imaging in vivo by planar scintigraphy facilitates the diagnosis of canine insulinomas. *Journal of Veterinary Internal Medicine* **19**, 168-176

Gorman, B., Charboneau, J. W., James, E. M., *et al*. (1986) Benign pancreatic insulinoma: preoperative and intraoperative sonographic localization. *American Journal of Roentgenology* **147**, 929-934

Goutal, C. M., Brugmann, B. L., Ryan, K. A., *et al*. (2012) Insulinoma in dogs: a review. *Journal of the American Animal Hospital Association* **48**, 151-163

Gouya, H., Vignaux, O., Augui, J., *et al*. (2003) CT, endoscopic sonography, and a combined protocol for preoperative evaluation of pancreatic Insulinomas. *American Journal of Roentgenology* **181**, 987-992

Günther, R. W., Klose, K. J., Rückert, K., *et al*. (1985) Localization of small islet-cell tumors. Preoperative and intraoperative ultrasound, computed tomography, arteriography, digital subtraction angiography, and pancreatic venous sampling. *Gastrointestinal Radiology* **10**, 145-152

Hirshberg, B., Livi, A., Skarulis, M. C., *et al*. (2000) Forty-eight-hour fast: the diagnostic test for insulinoma. *The Journal of Clinical Endocrinology & Metabolism* **85**, 3222-3226

Imhof, H. & Frank, P. (1977) Pancreatic calcifications in malignant islet cell tumors. *Radiology* **122**, 333-337

Johansen, K. (1979) Insulinoma: clinical manifestations, diagnosis and treatment. The significance of the prolonged fasting test and of the fasting blood glucose-insulin relationship. *Journal of Endocrinological Investigation* **2**, 285-290

Klöppel, G. & U Heitz, P. (1988) Pancreatic endocrine tumors. *Pathology, Research and Practice* **183**, 155-168

Kruth, S. A., Feldman, E. C. & Kennedy, P. C. (1982) Insulin-secreting islet cell tumors: establishing a diagnosis and the clinical course for 25 dogs. *Journal of the American Veterinary Medical Association* **181**, 54-58

Leifer, C. E., Peterson, M. E. & Matus, R. E. (1986) Insulin-secreting tumor: diagnosis and medical and surgical management in 55 dogs. *Journal of the American Veterinary Medical Association* **188**, 60-64

Liu, Y., Song, Q., Jin, H. T., *et al*. (2009) The value of multidetector-row CT in the preoperative detection of pancreatic insulinomas. *La Radiologia Medica* **114**, 1232-1238

Mai, W. & Cáceres, A. V. (2008) Dual-phase computed tomographic angiography in three dogs with pancreatic insulinoma. *Veterinary Radiology and Ultrasound* **49**, 141-148

Nelson, R. W. (2014) Disorder of the endocrine pancreas. In: Small Animal Internal Medicine. 5th edn. Eds R. W. Nelson and C. G. Couto, Mosby Inc. (Elsevier), Missouri, MO. p 817

Noone, T. C., Hosey, J., Zeynep, F., *et al*. (2005) Imaging and localization of islet-cell tumours of the pancreas on CT and MRI. *Best Practice & Research. Clinical Endocrinology & Metabolism* **19**, 195-211

O'Brien, T. D., Hayden, D. W., O'Leary, T. P., *et al*. (1987) Canine pancreatic endocrine tumors: immunohistochemical analysis of hormone content and amyloid. *Veterinary Pathology* **24**, 308-314

Okabayashi, T., Shima, Y., Sumiyoshi, T., *et al*. (2013) Diagnosis and management of insulinoma. *World Journal of Gastroenterology* **19**, 829-837

Polton, G. A., White, R. N., Brearley, M. J., *et al*. (2007) Improved survival in a retrospective cohort of 28 dogs with insulinoma. *The Journal of Small Animal Practice* **48**, 151-156

Rayamajhi, S. J., Lee, J., Mittal, B. R., *et al*. (2017) Cross sectional and nuclear medicine imaging of pancreatic insulinomas. *Abdominal Radiology* **42**, 531-543

Robben, J. H., Pollak, Y. W. E. A., Kirpensteijn, J., *et al*. (2005) Comparison of ultrasonography, computed tomography, and single-photon emission computed tomography for the detection and localization of canine Insulinoma. *Journal of Veterinary Internal Medicine* **19**, 15-22

Sheth, S., Hruban, R. K. & Fishman, E. K. (2002) Helical CT of islet cell tumors of the pancreas: typical and atypical manifestations. *American Journal of Roentgenology* **179**, 725-730

Tobin, R. L., Nelson, R. W., Lucroy, M. D., *et al*. (1999) Outcome of surgical versus medical treatment of dogs with beta cell neoplasia: 39 cases (1990-1997). *Journal of the American Veterinary Medical Association* **215**, 226-230

Trifonidou, M. A., Kirpensteijn, J. & Robben, J. H. (1998) A retrospective evaluation of 51 dogs with Insulinoma. *Veterinary Quarterly* **20**, 114-115

Zhu, L., Xue, H., Sun, Z., *et al*. (2017) Prospective comparison of biphasic contrast-enhanced CT, volume perfusion CT, and 3 Tesla MRI with diffusion-weighted imaging for insulinoma detection. *Journal of Magnetic Resonance Imaging* **46**, 1648-1655

17485827, 2021, 7, Downloaded from https://onlinelibrary.wiley.com/doi/10.1111/jsap.13336 by LIN YI CHUN - Readcube-Labtiva , Wiley Online Library on [21/01/2026]. See the Terms and Conditions (https://onlinelibrary.wiley.com/terms-and-conditions) on Wiley Online Library for rules of use; OA articles are governed by the applicable Creative Commons License